

# Asian Resonance

## Use of Buccal Fat Pad for Maxillary Defects



**Shefali Arora**

Senior Lecturer,  
Deptt. of Oral & Maxillofacial  
Surgery,  
Swami Devi Dyal Dental  
College & Hospital,  
Barwala, Haryana.



**Devinder Preet Singh**

Senior Lecturer,  
Deptt. of Orthodontics and  
Dentofacial Orthopedics,  
Dr Harvansh Singh Judge Institute  
of Dental Sciences,  
Panjab University,  
Chandigarh.

### Abstract

The buccal pad of fat represents a specialized type of fat termed as syssarcosis, a fat that enhances inter-muscular motion. The present study was undertaken to evaluate the efficacy of pedicled buccal fat pad in closure of oroantral communication / fistula / maxillary defects and to evaluate the advantages of buccal fat pad over Von Rehrmann buccal flap operation for closure of oroantral communication / fistula. A minimum of 20 patients with the age ranged between 20 – 70 years (mean age 37.6 yrs) were selected and randomly divided into two groups of 10 patients each. The study concluded that BFP seems to be one of the safest reconstructive methods for small to medium sized intraoral defects. It should also be considered a reliable backup procedure in the event of failure of Von Rehrmann flap.

**Keywords :** Buccal Fat Pad, Maxillary Defects, Von Rehrmann Flap.

### Introduction

The buccal fat was first described by **Heister (1732)**<sup>1</sup> who believed this to be glandular in nature. **Bichat (1802)**<sup>2</sup> is credited with recognizing the true fatty nature of the buccal fat. According to **Sicher (1965)**<sup>3</sup> it is rounded, biconvex structure limited by a thin but distinctive capsule. The buccal pad of fat represents a specialized type of fat termed as syssarcosis, a fat that enhances inter-muscular motion. It lines the masticator space and is intimately associated with the muscles of mastication, facial nerve and parotid duct. The buccal fat pad consists of a main body and four extensions, buccal, pterygoid, superficial and deep temporal. The main body is situated deeply along the posterior maxilla and upper fibers of the buccinator. The buccal extension lies superficially within the cheek and is largely responsible for cheek fullness. The pterygoid extension lies deep to the medial aspect of the mandibular ramus, resting between the ramus and the lateral surfaces of the medial and lateral pterygoid muscles. The buccal extension is the largest segment accounting for 30-40% of the total weight. The body is slightly smaller, representing 25-30% of total weight. The sizes of the pterygoid and deep temporal extension are inconsistent but are usually smaller than either body or buccal extension. The buccal fat in the cheek is enclosed in a fascial envelope derived from masseteric fascia. According to **Tideman et al (1986)**<sup>4</sup> the blood supply to the buccal fat pad is derived specifically from the buccal and deep temporal branches of the maxillary artery, the transverse facial branches of the superficial temporal artery and from small branches of the facial artery.

The buccal fat pad can be exposed safely through an intraoral incision. According to **Stuzin et al (1990)**<sup>5</sup> the incision should be high in the maxillary vestibule, beginning above the second molar, extending posteriorly for 2 cm and is made 5 mm above the attached gingiva of the second molar and extends through mucosa, buccinator muscle to expose the periosteum. According to **Lijie F (2002)**<sup>6</sup> BFP began epithelializing within 2-4 weeks and was completely epithelialized within 4-6 weeks depending on the size of defects.

Present study was undertaken to evaluate the efficacy of pedicled buccal fat pad in closure of oroantral communication / fistula / maxillary defects and to evaluate the advantages of buccal fat pad over Von Rehrmann buccal flap operation for closure of oroantral communication or fistula.

### Aims and Objectives

1. To evaluate the efficacy of pedicled buccal fat pad in closure of oroantral communication / fistula or maxillary defects.
2. To evaluate the advantages of buccal fat pad over Von Rehrmann

# Asian Resonance

buccal flap advancement operation for closure of oroantral communication or fistula.

## Review of Literature

**Moczair L (1930)**<sup>7</sup> proposed the trapezoidal buccal sliding flap that produces minimal change in the depth of the vestibular sulcus. This flap is shifted one tooth distally to reduce tension on the vestibular tissues. He said that the disadvantage of this technique is that when used in a dentate patient, bone is exposed on the facial aspect of the adjacent tooth, predisposing it to periodontal disease and hence is more appropriately used in edentulous patients.

**Rehrmann A (1936)**<sup>8</sup> proposed the buccal advancement flap. He advocated a trapezoidal flap, with its base at the buccal sulcus to maintain adequate blood supply. Following reflection of the flap from the underlying bone, small horizontal relieving incisions through periosteum at the base of the flap may allow for greater lengthening. He said that the major drawback of this technique is reduction in vestibular depth. However, he states that in most cases, the buccal sulcus reshapes in 4-8 weeks, but upto 40% of patients may suffer permanent vestibular loss.

**Baumann A et al (2000)**<sup>9</sup> evaluated the use of buccal fat pad in the reconstruction of the defects of the hard and soft palate in 29 patients. Indications for the use of BFP in his study was oroantral fistula, defects resulting from cyst excision or tumour resection, palatal cleft defects and covering of bone grafts. The author stated that the BFP is very useful as an oral layer in closure of fistulas in cleft patients. .

**Alkan A et al (2003)**<sup>10</sup> used the BFP as a pedicled graft in the reconstruction of medium sized intraoral defects in 26 patients. He used it for 15 OAC, 5 defects resulting from tumour resection and 6 defects resulting from cyst excision. The author stated that the size of BFP is important in the success of the procedure rather than preservation of the thin capsule, which partially provides the blood supply.

**Dolanmaz M et al (2004)**<sup>11</sup> evaluated the use of BFP in the closure of oroantral communication in 75 patients. No postoperative aesthetic deformity, limitation of maximal interincisal opening, infection in sinus or fat tissue or significant narrowing of the vestibular sulcus in the long term period was observed clinically. It was also concluded that age, sex and body weight have no impact on healing. The author stated that no vestibular sulcus narrowing occurs as in buccal advancement flap. Unlike palatal flap cases, there is no secondary healing areas that require a long and painful healing period.

**Amin MA (2005)**<sup>12</sup> evaluated the use of BFP in the reconstruction and prosthetic rehabilitation of oncological maxillary defects in 24 patients. He advocated that the defect after resection of a tumor can be reduced in size by local approximation of tissues, enabling easier repair with the BFP. He advocated the use of a split skin graft to line the oral side of graft, in conjunction with protection by an acrylic cover plate.

**George J et al (2006)**<sup>13</sup> used the buccal pad of fat for reconstruction of defects of the buccal mucosa, alveolar ridge and palate. The indications of BFP were 7 cases of OAF and 3 cases of defects resulting from tumour resection. The maximum size of the defect was 5x4 cms in their study. The author concluded that BFP is a readily available tissue for the closure of small to medium sized oral defects with simple harvesting technique, minimum complications and a good success rate.

**Haraji A (2007)**<sup>14</sup> evaluated the use of BFP for oroantral communication closure. He noticed that in all patients OAF was closed and healed without any aesthetic disadvantages or disturbances of masticatory function. He concluded that BFP was useful for OAF closure without any disturbance and scarring in the vestibule as compared to buccal advancement flap.

## Material and Methods

A minimum of 20 patients were selected from those reporting to the outpatient Department of Oral and Maxillofacial Surgery, Swami Devi Dyal Dental College and Hospital, Barwala, Panchkula. The patients were randomly divided into two groups of 10 patients each.

Group I - Buccal fat pad was used

Group II - Von Rehrmann Buccal advancement flap was used.

## Inclusion Criteria

1. Patients who reported with oroantral communication or oroantral fistula or maxillary defects resulting from cyst excision or tumour resection were included in the study.
2. Patients with a history of unsuccessful attempt at fistula closure with Von Rehrmann buccal flap advancement operation were included in group I in the study.
3. Patients were selected randomly irrespective of age, sex, religion and socioeconomic status.

## Exclusion Criteria

1. Medically compromised patients who have uncontrolled systemic diseases

## Operative Technique

The surgery was performed under LA with sedation or general anesthesia.

2. In patients with oroantral fistula, an incision was made around the fistulous tract 3- 4mm marginal to the orifice as the soft tissue aperture of the communication is almost always smaller, than the diameter of bony defect (Fig. 3A). The entire epithelized tract along with associated antral polyps was dissected and excised gingival margins freshened with blade No. 11.
3. Two divergent incisions were taken with blade no. 15 from each side of orifice into vestibule (Fig. 3A). If a Caldwell luc procedure was needed, the anterior vertical incision was extended horizontally to the canine region.
4. A trapezoidal mucoperiosteal flap was reflected from the alveolar process and lateral wall of the maxilla (Fig. 3B).

# Asian Resonance

5. Maxillary sinus was carefully inspected for evidence of infection through fistula under good illumination. In case, any antral pathology was present Caldwell-Luc procedure was carried out before the final closure of fistula.

## Caldwell-Luc Operation

### Indications

1. Removal of root fragments, teeth or foreign body or antrolith from the maxillary sinus
2. To treat chronic maxillary sinusitis with hyperplastic lining and polypoid degeneration of the mucosa
3. Removal of cyst or benign growth from the maxillary sinus.
4. Management of hematoma in the maxillary sinus and to control post-traumatic hemorrhage in the sinus.
5. Along with closure of chronic oroantral fistula, associated with chronic maxillary sinusitis.

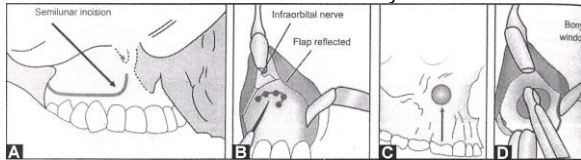


Figure 1

1. Intraoral incision for Caldwell Luc operation
2. Creation of bony window with drill
3. Perforation area for window
4. Enlarging the bony window at the anterior maxillary wall with rongeur or bur

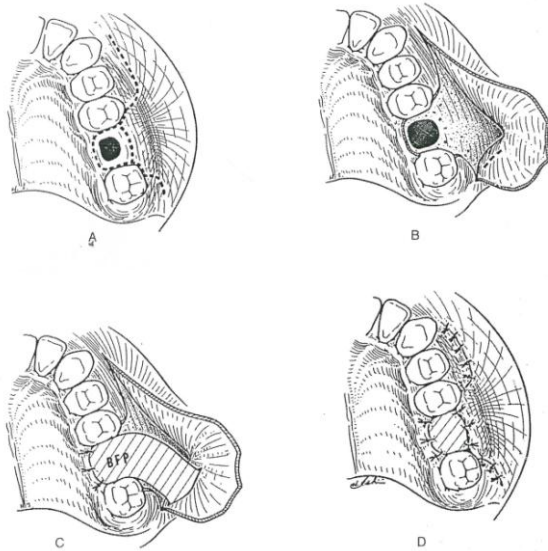


Figure 2 Buccal Fat Pad Closure of an Oroantral Fistula

1. Planned incision
2. Full thickness flap reflected
3. Small incision in the posterior portion of the flap for advancement of the BFP to cover the defects
4. Replacement of mucoperiosteal flap to its original position.

## Caldwell-Luc Surgical Procedure (Fig; 1)

A semilunar incision was made in the buccal vestibule from canine to second molar area just above the gingival attachment (Fig. 1A).

Mucoperiosteal flap was elevated with the help of periosteal elevator till the infraorbital ridge. An opening or window was created in the anterior wall of the maxillary sinus with the help of chisel or dental drills (Fig. 1B). The opening was enlarged carefully in all directions with Rongeur forceps (Fig. 1D). The size obtained was about the size of the index finger to facilitate the palpation of the sinus lining with the introduction of index finger into the sinus cavity.

1. Maxillary sinus was inspected for evidence of infection either through fistula or by illumination. Any polypoid masses or other diseased tissue was removed.
2. Antrum was gently irrigated with normal saline.
3. Hemorrhage was arrested to avoid formation of hematoma
4. The mucoperiosteal flap was sutured into position across the fistula with interrupted sutures.

## Buccal Fat Pad Operation (Fig. 2)

A 1 cm vertical incision was made on the periosteum dissected from the posterior aspect of zygomatic buttress in the second molar region (Fig. 2B). A curved haemostat was introduced through the periosteal incision aiming cranially in the region of third molar and then withdrawn, wide open, in such a way that a submucosal tunnel was created. This manoeuvre was repeated, if necessary, until the BFP appeared in the mouth.

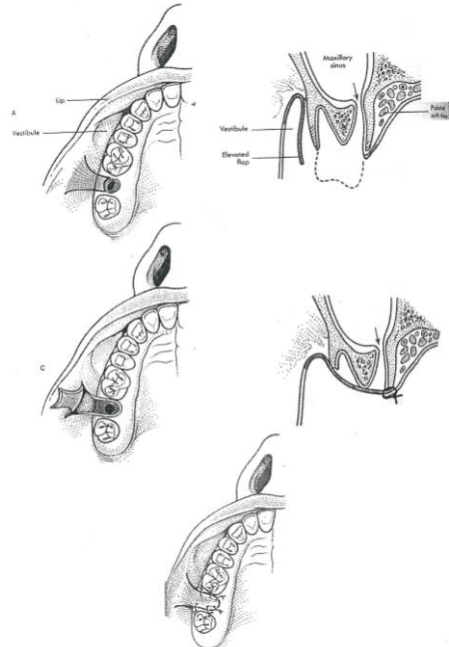


Fig . 3 : Incision For Closure of Fistula with Buccal Flap Advancement Procedure

1. 3A) Fistulous tract excised. Margins of flap wide enough to rest on sound bone when advanced to cover osseous defects.

2. 3B) Elevated buccal flap. Flap released to depth of labial vestibule. If necessary, periosteum incised on deep surface of flap to allow advancement of soft tissue to cover osseous defect without placing flap under tension
3. 3C) Advanced buccal flap. Flap position with minimal tension and margins supported by underlying bone to ensure adequate closure of fistulous tract.
4. 3D) Cross section of buccal flap closure of oroantral fistula
5. 3E) Buccal flap advanced over alveolar process and sutured to palatal mucosa to close fistulous tract.

After the BFP is mobilized intraorally by blunt dissection, suction was discontinued to prevent the aspiration of the fat. Buccal fat tissue was then advanced gently to the osseous defect area and secured to the palatal mucosa with suture material without tension (Fig. 2C).

Finally, the mucoperiosteal flap was replaced in its original position without tension (Fig. 2D). The fat tissue in the perforation area was left exposed in the oral cavity.

### **Von Rehrmann Buccal Flap Advancement Operation (Fig. 3)**

Mucoperiosteal flap was reflected (Fig. 3B). The bony margin of the alveolar ridge was inspected and reduction and smoothing of the same was carried out. If the buccal mucoperiosteal flap falls short of covering the fistula; the flap was advanced (Fig. 3C). A horizontal releasing incision was made in the periosteum, as high as possible to allow advancement of the buccal flap. Only those areas of periosteum which were preventing its advancement were cut.

### **Post-Operative**

Postoperatively all patients received antibiotics, analgesics, nasal decongestants and soft diet. Patients were instructed to avoid sneezing, exploring wound with tongue or deliberately sucking air or fluid through it and to avoid nose blowing in early stages. Patients were called for removal of sutures 7 to 10 days postoperatively. Patients were reviewed regularly to observe progress, clinically and radiologically.

### **Parameters to be Evaluated**

1. Vestibular Depth
2. Infection
3. Fistula Recurrence / Wound dehiscence
4. Healing process

### **Method of Evaluation of Parameters**

- A. Clinical Evaluation
- B. Radiological Evaluation

### **A. Clinical Evaluation**

- a) Preoperative Evaluation
- b) Postoperative Evaluation

### **Preoperative Evaluation**

1. Vestibular Depth

It was measured with the help of a divider from the free gingival margin to the greatest depth of the mucobuccal fold.

### **Postoperative Evaluation**

1. Vestibular Depth: It was measured with the help of a divider from the free gingival margin to the greatest depth of the mucobuccal fold at interval of 1 week, 6 weeks and 3 months.
2. Infection : Presence of infection was noted at the surgical site at intervals of 1 week, 6 weeks and 3 months as :Present/Absent
3. Fistula Recurrence : Fistula recurrence was noted at the surgical site at intervals of 1 week, 6 weeks and 3 months as :Present/Absent
4. Healing Process was evaluated at the surgical site at intervals of. 1 week, 6 weeks and 3 months post operatively for the
  - I. Colour of orally exposed fat / Von rehrmann flap
  - II. Partial Necrosis of buccal fat pad / Von rehrmann flap as :Present/Absent
  - III. Total necrosis of buccal fat pad / Von rehrmann flap as :Present/Absent
  - IV. Dehiscence of buccal fat pad / Von rehrmann flap as:Present/Absent
  - V. Time taken for complete epithelization of buccal fat pad

### **B. Radiological Evaluation**

It was based on the interpretation of the occipitomenal view and intraoral periapical radiograph.

### **1. Preoperative Evaluation**

It was based on the interpretation of the intra oral periapical radiograph and the occipitomenal view.

- i) The intraoral periapical radiograph was evaluated for the following parameters
  - a) Tooth or root or foreign body in the sinus cavity as: Present/Absent
  - b) Disruption of the cortical outline of floor of maxillary sinus as: Present/Absent
- ii) The occipitomenal view was evaluated for the following parameters
  - a) Haziness/opacification of maxillary sinus as :Present/Absent
  - b) Thickening of mucosa of the bony walls of maxillary sinus as :Present/Absent
  - c) Disruption of cortical outline of the maxillary sinus as:Present/Absent

### **2. Postoperative Evaluation**

It was based on the interpretation of the occipitomenal view. The radiograph was assessed postoperatively at intervals of 1 week, 6 weeks and 3 months in all the patients. The right and left sinus was compared to each other.

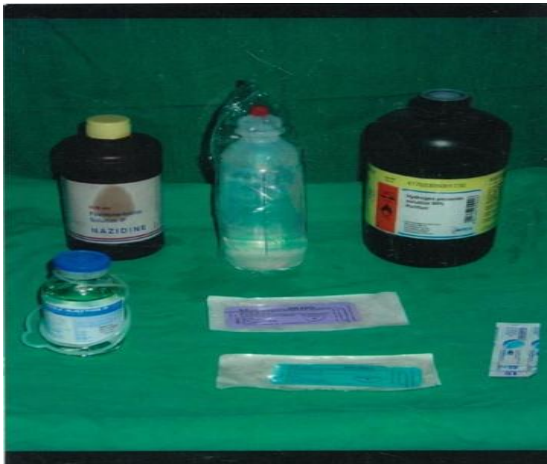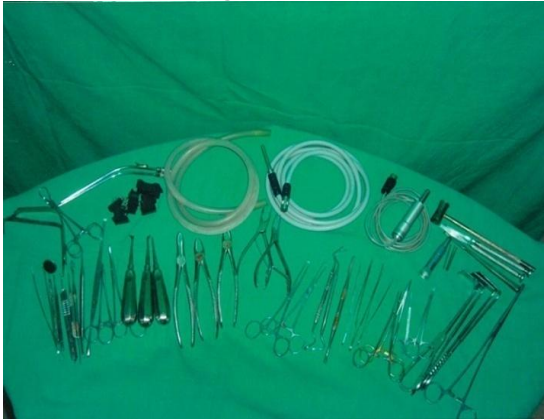The occipitomenal view was evaluated for the following parameters

1. Haziness/opacification of maxillary sinus as:Present/Absent
2. Thickening of mucosa of the bony walls of maxillary sinus as:Present /Absent
3. Disruption of cortical outline of the maxillary sinus as: Present/Absent



# Asian Resonance

Results of above parameters were analyzed statistically.  
Armamentarium (Fig. 4)



1. Sponge holding forcep
2. Mouth mirror
3. Explorer
4. Tweezer
5. Towel clips
6. Suction tip and tube
7. Bard parker handle and blade number 15
8. Mucoperiosteal elevators
9. Bone curette
10. Hemostats (curved and straight)
11. Allis tissue forceps
12. Extraction forceps and elevators
13. Chisel, osteotome and mallet
14. Retractors and tongue depressors
15. Needle holder
16. Adson's tissue holding forceps
17. Scissors
18. Suture material (vicryl 3-0, mersilk 3-0)
19. Hand piece and micromotor
20. Mouth prop
21. Fiberoptic light
22. Hydrogen peroxide
23. Betadine
24. Metrogyl infusion
25. Normal saline

Case Report 1  
Buccal Fat Pad (Fig. 5)

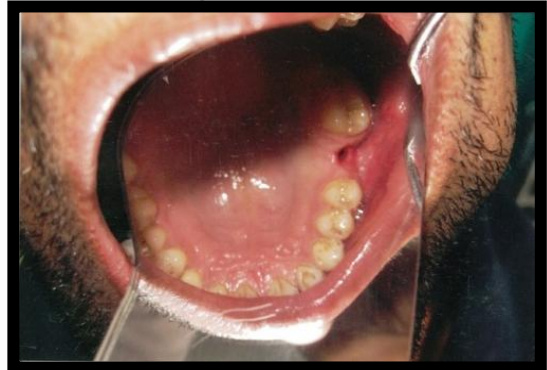

FIG. 5(a) : Preoperative intraoral view showing oroantral fistula in relation to left upper first molar

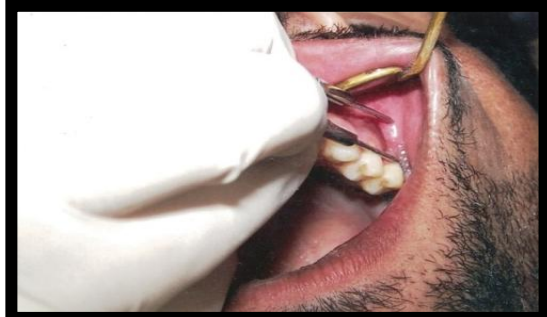

FIG. 5(b) : Preoperative Measurement of Vestibular Depth

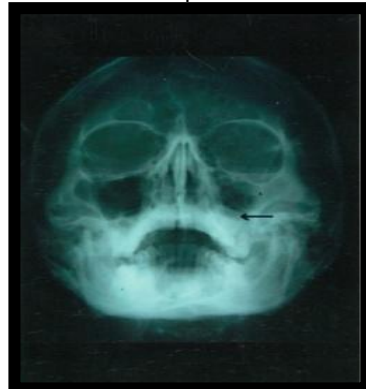

FIG. 5(c) : Pre Operative Occipitomental View



FIG. 5(d) : Preoperative Intraoral Periapical Radiography

# Asian Resonance

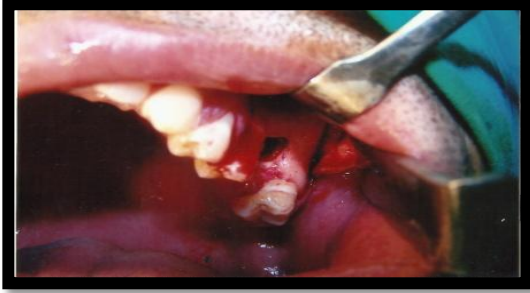

FIG. 5(e) : Excision of the Fistulous tract

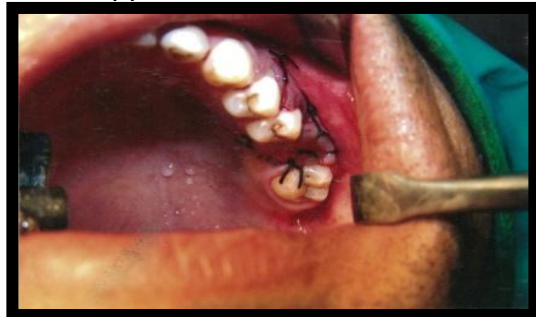

FIG. 5(f) : Closure

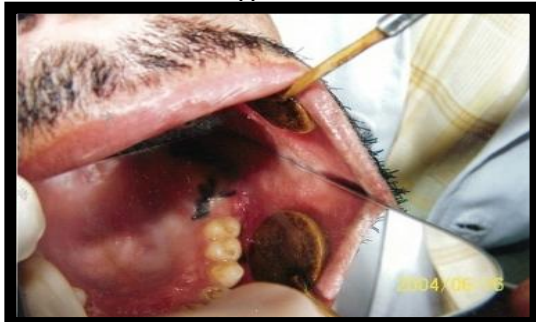

FIG. 5(g) : Postoperative Intraoral View (1 week)

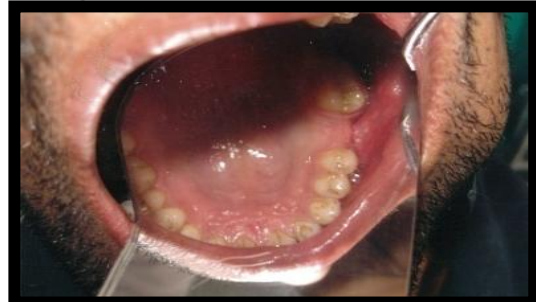

FIG. 5(h) : Postoperative Intraoral View (3 Months)

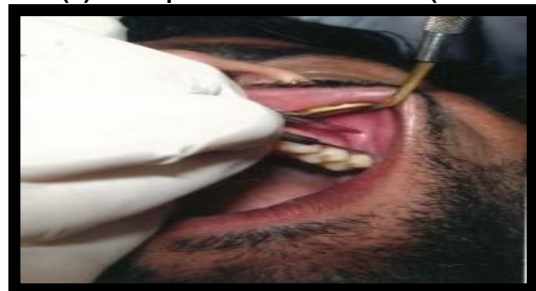


FIG. 5(i) : Postoperative Vestibular Depth (3 months)

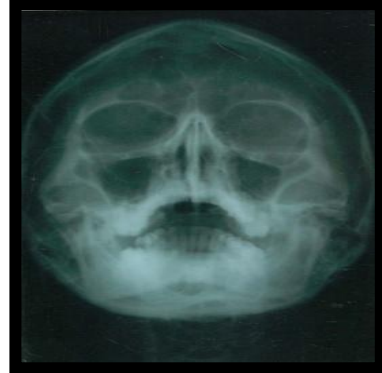

FIG. 5(j) : Postoperative Occipitomenal view (3 months)

## Case Report 2

### Von Rehrmann Buccal Advancement Flap (FIG. 6)

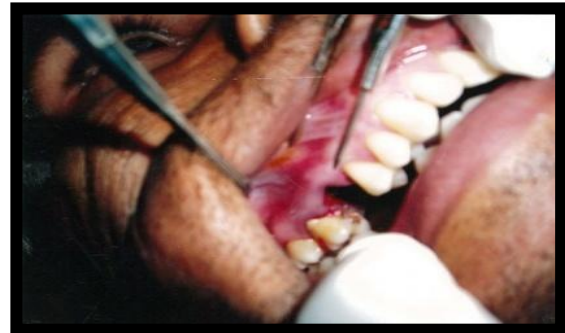

FIG. 6(a) : Preoperative Measurement of Vestibular Depth

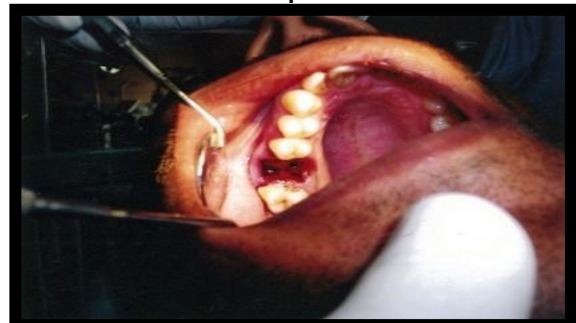

FIG. 6(b) : Preoperative Intraoral View Showing Oroantral Communication In Relation to Right Upper First Molar

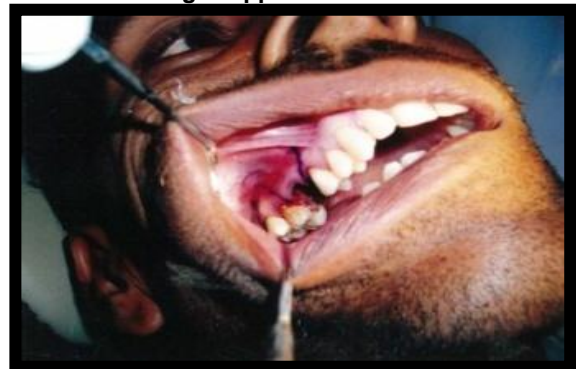

FIG. 6(c) : Incisal Marking



# Asian Resonance

## Observation and Results

The present study was undertaken on 20 patients, 10 males (50%) and 10 females (50%), who reported with oroantral communication or fistula or maxillary defects resulting from cyst excision or tumour resection. All the patients with the age ranged between 20 – 70 years (mean age 37.6 yrs) were evaluated clinically and radiographically.

All the patients were assessed preoperatively and postoperatively for various parameters like vestibular depth, infection, fistula recurrence. Healing process of BFP, haziness or opacification of maxillary sinus, thickening of mucosa of bony walls of maxillary sinus and disruption of cortical outline of maxillary sinus both clinically and radiographically. Postoperative evaluation was performed at various time intervals viz 1 week, 6 weeks and 3 months.

The patients were randomly divided into two groups of 10 patients each with age groups ranging from 20 to 70 years with maximum number of patients falling into the age group of 20-30 years. In Group I preoperative diagnosis was oroantral fistula in 6 patients followed by maxillary sinus cyst in 3 patients and oroantral communication in 1 patients. In Group II preoperative diagnosis was oroantral communication in 6 patients of cases followed by oroantral fistula in 4 patients. In Group I right side was involved in 6 patients and left side was involved in 4 patients. In Group II left side was involved in 6 patients and right side was involved in 4 patients. In Group I buccal fat pad was used and in Group II von Rehmann buccal advancement flap was used.

Vestibular depth was measured clinically both preoperatively and postoperatively at intervals of 1 week, 6 weeks and 3 months with the help of a divider NM from the free gingival margin to the greatest depth of the mucobuccal fold. Comparative analysis of reduction in vestibular depth in Group I and Group II patients was done postoperatively at intervals of 1 week, 6 weeks and 3 months. Student's t test was used for statistical analysis which showed a value of -7.794 and p value of 0.000 at 1 week which was significant. At 6 weeks the value was -2.496 and p value was 0.022 which was significant. At 3 months the value obtained was -3.857 and p value was 0.001 which was significant (Table 1).

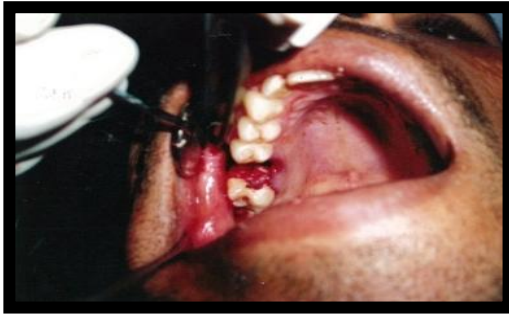

FIG. 6(d) : Von Rehmann Flap Raised

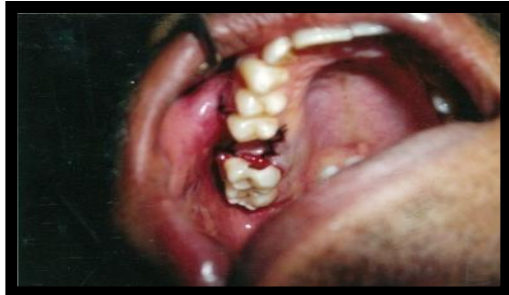

FIG. 6(e) : Closure

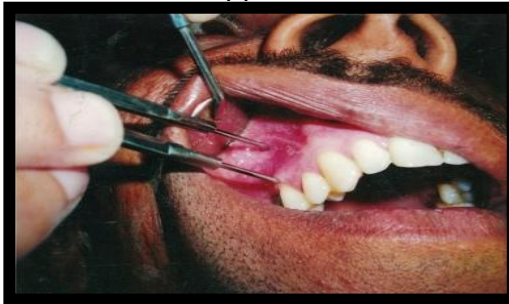

FIG. 6(f) : Postoperative Measurement of Vestibular Depth (3 months)

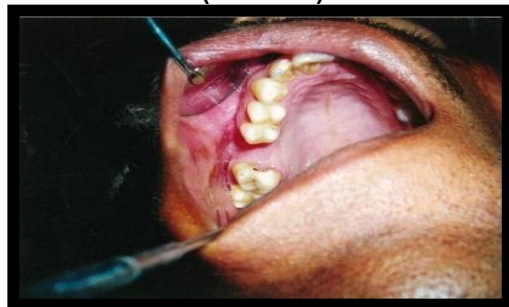

FIG. 6(g): Postoperative Intraoral View (3 months)

Table 1 : Significance of Difference of Reduction In Vestibular Depth Based on Type of Treatment (BFP V/s VRF flap)

S. No.	Reduction in Vestibular Depth	t	df	Mean difference ± SD	P value	Significance
1	1 week	-7.794	18	-1.8 ± 0.23	0.000	Significant
2	6 weeks	-2.496	18	-0.6 ± 0.24	0.022	Significant
3	3 months	-3.857	18	-0.9 ± 0.23	0.001	Significant

Post operative evaluation showed absence of infection and fistula recurrence in 100% of patients in both group I and group II at intervals of 1 week, 6 weeks and 3 months postoperatively. Postoperative evaluation of colour of orally exposed BFP was done

in Group I patients at 1 week, 6 weeks and 3 months. At 1 week colour of orally exposed BFP was red in 6 cases, followed by yellow in 4 cases. At 6 weeks and 3 months colour of orally exposed BFP was pink in all 10 cases. Postoperative evaluation of colour of VRF

# Asian Resonance

flap was done in group II patient at 1 week, 6 week and 3 months postoperatively. At 1 week the colour of VRF flap was deep pink in all 10 patients. At 6 weeks and 3 months the colour of VRF flap was pink in all 10 patients. Partial necrosis / Total necrosis and Dehiscence of BFP/ VRF flap was evaluated at 1

week, 6 weeks and 3 months postoperatively in group I & II patients and was not seen in any patient.

Time taken for complete epithelization of BFP was evaluated postoperatively in Group I patients and was 3-4 weeks in 9 patients followed by 2-3 weeks in 1 patient. The range was 3-4 weeks with mean ± SD of 3.53 ± 0.42 (Table 2).

**TABLE 2: Postoperative evaluation of time taken for complete epithelization of BFP in Group I patients (Clinical) p**

S. No.	Time taken for epithelization (in weeks)	Number of Patients	Percentage Distribution	Minimum Time Taken (in weeks)	Maximum Time Taken (in weeks)	Mean Time ± SD
1	0-1	0	0	3.0	4.0	3.53 ± 0.42
2	1-2	0	0			
3	2-3	1	10			
4	3-4	9	90			
5	4-5	0	0			
6	5-6	0	0			

Pre-operative evaluation of teeth or root or foreign body in the maxillary sinus was done on an intraoral periapical view in Group I & II patients. In Group I patients a root was present in the maxillary sinus in 1 patient and was absent in 9 patients. In Group II patients, teeth or root or foreign body in the maxillary sinus was absent in 10 patients. Pre-operative evaluation of disruption of cortical outline of floor of maxillary sinus was done on an intraoral periapical view in Group I & II patients. The cortical outline of the floor of maxillary sinus was found to be disrupted in 100% of patients in both Group I & II patients on the intraoral periapical view.

months in both Group I & II patients. Pre-operative evaluation of haziness/opacification in Group I patient showed presence of haziness/ opacification in 8 patients and absence in 2 patients. Group II patients showed presence of haziness/ opacification in 7 patients and absence in 3 patients. At 1 week post operative both Group I & II patients showed presence of haziness/ opacification in 7 patients and absence in 3 patients. (Table 3) At 6 week post operative Group I patients showed presence of haziness/ opacification in 3 patients and absence in 7 patients in contrast to Group II patients which showed absence of haziness/ opacification in 10 patients. At 3 months post operative both Group I & II patients showed absence of haziness/opacification in all the patients. (Table 3)

Haziness/opacification of maxillary sinus was evaluated on occipitontal view, pre-operatively and post operatively at intervals of 1 week, 6 weeks and 3

**Table 3 : Postoperative Evaluation of Haziness/ Opacification of Maxillary Sinus on Occipitontal View in Group I and II Patients (Radiographic)**

S. No.	Haziness/ Opacification of Maxillary Sinus	Key	No. of Patients		Percentage Distribution	
			Group I	Group II	Group I	Group II
1	1 week postoperative	0	3	3	30	30
		1	7	7	70	70
2	6 weeks postoperative	0	7	10	70	100
		1	3	0	30	0
3	3 months postoperative	0	10	10	100	100
		1	0	0	0	0

0 = Absent ; 1 – Present

Thickening of mucosa of bony walls of maxillary sinus was evaluated on occipitontal view, preoperatively and postoperatively at intervals of 1 week, 6 weeks and 3 months in both Group I & II patients. Preoperative evaluation showed presence of thickening in 7 patients and absence in 3 patients in contrast to Group II patients which showed presence in 2 patients and absence in 8 patients. At 1 week post operative Group I patients showed presence of thickening in 7 patients and absence in 3 patients in contrast to Group II patients who showed presence in 2 patients and absence in 8 patients. (Table 4) At 6 weeks post operative Group I patient showed presence of thickening in 4 patients and absence in 6

patients in contrast to Group II patients who showed absence of thickening in 10 patients. At 3 months postoperative Group I patients showed presence of thickening in 1 patient and absence in 9 patients in contrast to Group II patients who showed absence of thickening in 10 patients. (Table 4)

Disruption of cortical outline of maxillary sinus was evaluated on occipitontal view, preoperatively and postoperatively at intervals of 1 week, 6 weeks and 3 months in both Group I & II patients and was found to be absent in all the patients.



**Table 4 : Postoperative evaluation of thickening of mucosa of bony walls of maxillary sinus on occipitomental view in group I and II patients (Radiographic)**

S. No.	Thickening of Mucosa of Bony Walls of Maxillary Sinus	Key	No. of Patients		Percentage Distribution	
			Group I	Group II	Group I	Group II
1	1 week postoperative	0	3	8	30	80
		1	7	2	70	20
2	6 weeks postoperative	0	6	10	60	100
		1	4	0	40	0
3	3 months postoperative	0	9	10	90	100
		1	1	0	10	0

0 = Absent ; 1 - Present

### Discussion

The present study was carried out to evaluate the efficacy of pedicled buccal fat pad in closure of oroantral communication or fistula or maxillary defects and to evaluate the advantages of buccal fat pad over Von rehrmann buccal flap advancement operation for closure of oroantral communication or fistula. In the present study, the patients were randomly divided into two groups each having 10 patients. In Group I patients, buccal fat pad was used and in Group II patients Von rehrmann flap was used. The age range of patients was from 20-70 years (mean age 37.6 yrs) which is consistent with the findings of **Haraji A (2007)**<sup>14</sup>.

The indication for the use of BFP in Group I patients was oroantral fistula in 6 (60 %) patients, maxillary sinus cyst in 3 (30 %) patients and oroantral communication in 1 (10 %) patients. This is similar to the findings of **Hanazawa Y (1995)**<sup>15</sup> who used BFP for 10 (71.4%) patients of oroantral fistula and communication and 4 (28.5%) patients of maxillary sinus cyst in his study. This is not consistent with the study by **Alkan A (2003)**<sup>10</sup> who used BFP for oroantral communication in 15 (57.69%) patients, maxillary sinus cyst in 6 (23.07%) and defects resulting from tumor resection in 5 (19.23%) patients. In the present study, no maxillary defects resulting from tumor resection were found and hence BFP was not used for this purpose. The indication for the use of Von Rehrmann flap in Group II patients was oroantral communication in 6(60%) patients and oroantral fistula in 4 (40%) patients which is in accordance with the study by **Killey and Kay (1972)**<sup>16</sup>.

Comparative evaluation of reduction in vestibular depth in Group I and Group II patients at intervals of 1 week, 6 week and 3 months postoperatively, showed that there was statistically significant difference in the two groups where BFP or Von rehrmann buccal advancement flap was used. At 1 week statistical analysis using the student's t test showed a value of -7.794 and p value of 0.000 which was significant. At 6 weeks the value was - 2.496 and p value was 0.022 which was also significant. At 3 months the value obtained was -3.857 and p value was 0.001 which was significant.(Table 1) This is in accordance with the study of **Hanazawa Y (1995)**<sup>15</sup> who showed little decrease in vestibular depth with the use of BFP. This is also consistent with the study of **Rehrmann A (1936)**<sup>8</sup> who demonstrated that the

major drawback of Von Rehrmann buccal advancement flap was reduction in vestibular depth.

Postoperative evaluation of infection in the present study showed absence of infection in 100% of patients in both the groups at all time intervals. This is consistent with the findings of **Dolanmaz M et al (2004)**<sup>11</sup> who reported no cases of infection in sinus or fat tissue postoperatively, after use of BFP in closure of oroantral openings in 75 patients. This is also in accordance with the findings of **Killey and Kay (1972)**<sup>16</sup> who analysed 362 oroantral fistula treated by surgical closure using the technique described by Rehrmann.

Postoperative evaluation of fistula recurrence in the present study showed absence of fistula recurrence in 100% of patients in both the groups at all time intervals. This is not consistent with the study by **Alkan A (2003)**<sup>10</sup> who reported a fistula recurrence in 1 patient in the reconstruction of oral defects with BFP. This is also not in accordance in the study by **Killey and Kay (1972)**<sup>16</sup> who reported fistula recurrence in 18 (4.9%) patients. This finding in the present study may be because of small sample size.

Postoperative evaluation of colour of orally exposed fat in the present study at 1 week showed that colour was red in 6 (60 %) patients and yellow in 4 patients which is consistent with the study by **Dolanmaz (2004)**<sup>11</sup> who stated that the colour of orally exposed BFP became yellow in 3 days and then gradually became red within 1 week, which was likely due to the formation of young granulation tissue. At 6 weeks and 3 months the colour of orally exposed fat was pink in 10 (100 %) patients which is consistent with the study by **Lijie F (2002)**<sup>6</sup>, who stated that regenerated mucosa became pink and similar in appearance to surrounding normal mucosa. Partial necrosis / total necrosis of BFP/VRF flap was evaluated at all time intervals postoperatively and was found to be absent in 10 patients (100%) in both the groups which is consistent with the study by **George J et al (2006)**<sup>13</sup> Dehiscence of BFP was evaluated at all time intervals postoperatively absent in all 10 patients which is in accordance with the study by **George J et al (2006)**<sup>13</sup>. Dehiscence of VRF flap was evaluated at all time intervals and was absent in all 10 patients which is not consistent with the study by **Killey and Kay (1972)**<sup>16</sup> who reported dehiscence in 18 (4.9%) patients. This finding in the present study may be because of small sample size, good

# Asian Resonance

sterilization measures and improved surgical protocols and materials.

Time taken for complete epithelization of BFP was evaluated postoperatively in Group I patients and was in the range of 3-4 weeks with a mean of 3.53 which is in accordance with a study by **Dolanmaz (2004)**<sup>11</sup> who showed similar results. This is also in accordance with the results of **Hanazawa Y (1995)**<sup>15</sup> who showed the histologic process of epithelization of the orally exposed fat tissue, based on small biopsy samples taken over the course of the healing process. He concluded, that the superficial layer of fat tissue became replaced by granulation tissue and is finally covered with stratified squamous epithelium migrating from the margin of the gingiva. In addition he stated that the original component of the active replacement by granulation tissue came from the highly vascularized fat tissue and from the fresh wound around the OAF.

Preoperative evaluation of tooth/root/foreign body in the maxillary sinus was done on an intraoral periapical radiograph in group I patient which revealed a root fragment within maxillary sinus in 1 (10%) patients. This is consistent with the study of **Dolanmaz G (2004)**<sup>11</sup> who saw 7 (9.3%) cases of tooth/root pushed into the maxillary sinus. A Caldwell Luc operation was subsequently planned and executed for the retrieval of the root piece. In group II patients teeth or root or foreign body in the maxillary sinus was absent in all 10 patients. This is not consistent with the study of **Killey and Kay (1972)**<sup>16</sup> who saw 113 (31.2%) cases of tooth/root/foreign body displaced into the antrum. This finding in the present study may be because of small sample size.

Preoperative evaluation of disruption of cortical outline of the floor of maxillary sinus on intraoral periapical view in both groups showed disruption of the floor in all 10 patients in both the groups.

Preoperative evaluation of haziness/opacification of maxillary sinus on an occipitomeatal view in Group I patients, in the present study showed presence of haziness/ opacification in 8 (80%) patients. At 1 week postoperative haziness / opacification was seen in 7 (70%) patients, which decreased to 3 (30%) patients at 6 weeks and was absent in all 10 patients at 3 months. Postoperative radiographic evaluation at 1 week, 6 weeks and 3 months, in the present study showed an increase in the radiologically healthy clear maxillary sinus, with time.

Preoperative evaluation of haziness/opacification of maxillary sinus on an occipitomeatal view in Group II patients in the present study showed presence in 7 (70%) patients. At 1 week postoperative haziness /opacification was seen in 7 patients and was found to be absent in all 10 patients at 6 weeks and 3 months postoperatively. In the present study postoperative radiographic evaluation at various time intervals showed an increase in the number of patients with radiologically healthy clear maxillary sinus with time. This finding is similar to the findings of

**Killey and Kay (1972)**<sup>16</sup> who showed, presence of haziness /opacification preoperatively in 84.5% patients. Postoperative radiographic evaluation in his study showed radiologically clear antrum in 216 (80%) patients, cloudy antrum in 11 (3.7%) and polyp formation in 1 (0.4%) patients after a follow up of 1 year. He stated that radiographic interpretation of haziness/opacification in maxillary sinus cannot be specific, owing to the fact that transudates, exudates or blood all produce a similar shadow on the radiograph. He stated that haziness/opacification may result from gross mucosal thickening or the presence of blood, pus, mass of polyps, osteoma, antralolith, cyst or tumors within the maxillary sinus.

Preoperative, evaluation of thickening of mucosa of bony walls of maxillary sinus on an occipitomeatal view in Group I patients showed presence in 7(70%) patients. Postoperatively, thickening was present in 7(70%) patients at 1 week, 4(40%) patients at 6 weeks which further decreased to 1(10%) patient at 3 months. In the present study, thickening of mucosa of bony walls of maxillary sinus was seen to resolve radiologically with time.

Preoperative evaluation of thickening of the mucosa of the bony walls of maxillary sinus on an occipitomeatal view in Group II patients showed presence in 2(20%) patients. Postoperatively, thickening was present in 2(20%) patients at 1 week and was absent in all 10 patients at 6 weeks and 3 months postoperatively. In the present study, thickening of mucosa of the bony walls of maxillary sinus was seen to resolve with time. This is similar to the results of **Killey and Kay (1972)**<sup>16</sup> who showed presence of thickening preoperatively in 44.47% of patients. Postoperative, radiographic evaluation in their study showed presence of thickening in 15.5% of patients after a follow up of 1 year. He stated that the thickening is brought about by allergic or infective stimulus which produce dilatation of the arterioles and capillaries, with increased permeability of the capillaries and this leads to oedema and water logging of the submucosa which becomes swollen. He concluded that this process is reversible in the early stages and therefore there is a variation in the size of the shadow cast by the mucosa as it is sometimes seen on consecutive radiographs. He further stated that transition to a chronic state occurs after a period of two weeks. Although the condition is curable, delay in therapeutic intervention adversely affects the prognosis. The lining membrane may suffer permanent injury and may be deprived of its capacity for functional recovery. He concluded that if dental disease is the sole cause of chronic sinusitis and there is no suspicion of preexisting allergic factors, then the removal of oral provocant should result in the complete recovery of the sinus mucosa.

Disruption of cortical outline of maxillary sinus was evaluated on an occipitomeatal view, preoperatively and postoperatively at intervals of 1 week, 6 weeks and 3 months in both groups and was found to be absent in all the patients (100%) in our study. This finding in the present study may be

# Asian Resonance

because of the fact that severe erosion of the walls of maxillary sinus is only seen on conventional radiographs when the disease is markedly advanced and the prognosis correspondingly unfavorable. According to **Killey & Kay (1975)**<sup>17</sup> on an occipitomenal projection, as much as 50% of the antral wall may be lost without any apparent alteration in the x-ray appearance.

The study concluded that because of ease of access, the rich blood supply and its abundance, the use of BFP can be considered a reliable and convenient method for closure of small or medium sized intraoral defects. Another advantage of the BFP when used for closure of oroantral fistula or communication is that there is less decrease in the vestibular depth than with the Von Rehrmann flap. Moreover, while this technique allows healing of oral mucosa, it also protects its normal anatomic architecture. Thus, the need for future operations could be eliminated in patients who may use a prosthesis.

The success of the BFP procedure depends on careful manipulation of the flap in order to maintain its thin capsule. Mechanical suction must be avoided once the BFP is exposed. Further blunt dissection preferably with 2 vascular clamps is mandatory. One to gently pull out the emergent part and the other to dissect the oral mucosa and other tissues surrounding the BFP. Secondly, one should be aware of the size limitations. Assuming that the BFP volume is 10 ml and its lowest thickness is 6 mm, defects greater than 60x50x30 mm cannot be guaranteed without producing flap necrosis or creating a new fistula. The mucosal approach must be the smallest necessary to allow for its removal and sutures should be tension free, to avoid partial necrosis at the edges. Lastly, due to its anatomical situation, the ideal defects to be reconstructed with the BFP are the maxillary defects from the premolar area to the maxillary tuberosity. Also soft and hard palate, superior alveolar rim, cheek mucosa and tonsillar fossa are suitable places to be employed (**Egyedi 1977**<sup>18</sup>, **Stajcic Z 1992**<sup>19</sup>, **Fujimura N 1990**<sup>20</sup> **Loh & Loh 1991**<sup>21</sup>).

In the light of these findings, the BFP should be used more often for various purposes in the future.

## Summary and Conclusion

The present study was undertaken to evaluate the efficacy of pedicled buccal fat pad in closure of oroantral communication or fistula or maxillary defects and to evaluate the advantages of buccal fat pad over Von Rehrmann buccal flap advancement operation for closure of oroantral communication of fistula. It was concluded that the advantages of BFP were

1. Ease of access
2. Rich blood supply
3. Minimal donor site morbidity Low rate of complications such as fistula recurrence, dehiscence, partial necrosis, total necrosis and infection.
4. Minimal decrease in the vestibular depth than with the Von Rehrmann flap

5. No denuded area requiring secondary granulation that may be painful, takes longer time to heal and leaves scars as is evident in case of palatal flaps.

Its sole disadvantage is that it can only be used once. The use of BFP in patients with prior local radiotherapy, malar hypoplasia, thin cheeks or Down's syndrome is contraindicated.

The success of the BFP procedure depends on several factors:

1. Careful manipulation of the flap in order to maintain its thin capsule.
2. Avoid mechanical suction once the BFP is exposed.
3. Blunt dissection preferably with 2 vascular clamps. One to gently pull out the emergent part and the other to dissect the oral mucosa and other tissues surrounding the BFP.
4. Sutures should be tension free, to avoid partial necrosis at the edges.

Therefore, we conclude that BFP seems to be one of the safest reconstructive methods for small to medium sized intraoral defects. It should also be considered a reliable backup procedure in the event of failure of Von Rehrmann flap.

## References

1. Heister, L (1732), *Compendium Anatomicum, Norimbergae, Germany*, G.C. Weberi, pp 146.
2. Bichat, F (1802), *Anatomic generale, appliqué a la physiologie et a la médecine*, Paris, France: Brosson, Gabon, et Cie.
3. Sicher, H (1965), *Oral Anatomy*, St. Louis Mosby, Vol. 194, pp 474.
4. Tideman, H, Bosanquet, A, Scott, J (1986), Use of the buccal fat pad as pedicled graft, *Journal of Oral Maxillofacial Surgery*, Vol. 44, pp 435-440.
5. Stuzin, J, Wagstrom, L, Kawamoto, H, Baker, T (1992), Wolfes anatomy and clinical applications of the buccal fat pad, *Plastic reconstructive surgery*, Vol. 85, pp 29-37.
6. Lijie, F, Guanfuc et al (2002), Clinical application and histological observation of pedicled buccal fat pad grafting, *Chinese Medical Journal*, Vol. 115, No. 10, pp 1556-59.
7. Moczar, L (1930), *Nuovomethodo operatiopela chisuradell a fistule del senso maxelloso di orgina dentale*, *Stamatol (Roma)*, Vol. 28, pp 1087-88.
8. Rehrmann, A (1936), *Eine method Zur schliessung von kielorhohlen perforation* *Dtsch Zahana rztz*, Vol. 39, pp 1136-39.
9. Baumann, A, Ewers, R (2000), Application of the buccal fat pad in Oral Reconstruction, *Journal of Oral Maxillofacial Surgery*, Vol. 58, pp 389-92.
10. Alkan, A, Dolanmaz, D (2003), The reconstruction of oral defects with buccal fat pad, *Swiss Med wkly*, Vol. 133, pp 465-70.
11. Dolanmaz, M, Tuz, H, Bayraktar, S, Erdem, E, Bajkul, T (2004), Use of pedicled buccal fat pad in the closure of oroantral communication : Analysis of 75 cases; *Quintessence Int*, Vol. 35, pp 241-46.
12. Amin, M.A. (2005), Use of the BFP in the reconstruction and prosthetic rehabilitation of

# Asian Resonance

- oncological maxillary defects, BJOMS, Vol. 43, pp 148-154.
13. George, J, Sumir, G, Viney, A(2006), Closure of oral defects with buccal pad fat, Journal of Maxillofacial and Oral Surgery, Vol. 5, pp 41-3.
  14. Haraji, A, Zare, R(2007), The use of buccal fat pad for oroantral communication closure, Journal of Mashhad Dental School, Mashhad University of Medical Sciences, Vol. 31, pp 9-11.
  15. Hanazawa, Y, Itoh, K, Mabashi, T, Sato,K(1995), Closure of oroantral communications using a pedicled buccal fat pad graft, Journal of Oral and Maxillofacial Surgery, Vol. 53, pp 771-75.
  16. Killey, H.C, Kay, L. W.(1972), An analysis of 362 cases of oroantral fistula treated by the method described by Von Rehrmann buccal flap operation, Int Surg, Vol. 57, pp 545-9.
  17. Killey, H.C, Kay, C. W.(1975), The maxillary sinus and it's dental implications, e.d. Bristol John Wright and Sons Ltd.
  18. Egyedi, P, Utilization of the buccal fat pad for closure of oroantral and oronasal communications,Journal of Maxillofacial Surgery, Vol. 5, pp 241-44.
  19. Stajcic, Z(1992), The buccal fat pad in the closure of oroantral communications: A study of 56 cases, Vol. 20, pp 193-7.
  20. FujiMora, N, Nagura, H, Enomoto, S(1990), Grafting of the buccal fat pad into palatal defects, Journal of Craniomaxillofacial Surgery, Vol. 18, pp 219-20.
  21. Loh, F.C, Loh, H.S(1991), Use of BFP for correction of intraoral defects. Journal of Oral and Maxillofacial Surgery, Vol. 49, pp 413-16.